

JOSEPH A. JACHIMCZYK, M.D., J.D.
FORENSIC PATHOLOGIST
ATTORNEY AT LAW
CHIEF MEDICAL EXAMINER



228-8311
EXT. 671 (DAY)
EXT. 212 (NIGHT)

OFFICE OF THE MEDICAL EXAMINER
OF HARRIS COUNTY

HARRIS COUNTY COURT HOUSE
HOUSTON, TEXAS 77002

AUTOPSY REPORT

Case 73 - 3378

August 15, 1973

PATHOLOGICAL DIAGNOSIS ON THE BODY


OF

Unknown #22

Asphyxia due to strangulation.

OPINION

It is our opinion that the decedent,
Unknown #22, came to his death as a
result of asphyxia due to strangulation -
Homicide.


Joseph A. Jachimczyk, M.D., J.D.
Chief Medical Examiner

(See Companion Cases 73 - 3376 and 73 - 3377)

POSTMORTEM EXAMINATION ON THE BODY OF
UNKNOWN #22

HISTORY: This unidentified white male body was found at approximately the same time that three other bodies were uncovered during the evening of August 9, 1973, near Lake Sam Rayburn in San Augustine County, Texas. One was identified as William Ray Lawrence. His body was not sent to the Harris County Morgue. The remaining three were sent to this morgue. (73-3376, 73-3377 and 73-3378.) The three bodies arrived at the Harris County Morgue at 1:00 p.m. on August 11, 1973.

AUTOPSY: The autopsy was performed by Chief Medical Examiner Joseph A. Jachimczyk, M.D., assisted by Assistant Medical Examiners Ethel E. Erickson, M.D., and G. Sheldon Green, M.D., and Dr. Paul G. Stimson, beginning at 10:15 a.m. on August 15, 1973, in the Harris County Morgue.

EXTERNAL APPEARANCE: The decomposing body was that of a young Caucasian male, measuring approximately 68 inches in length and weighing a residual 75 pounds, submitted in a crashbag. The body was covered with white embalmer's preservative powder. The head was covered with fairly short dark brown hair, measuring up to 3-1/2 inches in length. The body had been previously autopsied. There were no clothes.

Complete postmortem X-rays of the body did not reveal the presence of any radiopaque objects.

INTERNAL EXAMINATION: Section: The body was opened through the previously made Y-shaped prior autopsy incision. The abdominal and thoracic viscera were re-examined. The body cavities emitted an unpleasant aroma.

HEART: The heart was decomposing.

LUNGS: The lungs together weighed 450 grams. They were collapsed and decomposing.

LIVER: The liver weighed 450 grams. The liver was mostly autolyzed. The gallbladder was empty.

Pancreas and Adrenals: The pancreas and adrenals were autolyzed.

SPLEEN: The spleen weighed 50 grams. There was postmortem decomposition.

GENITOURINARY TRACT: The kidneys together weighed 50 grams. They were autolyzed.

GASTROINTESTINAL TRACT: Most of the intestines were eaten away with lime. The stomach was empty.

BONES: There was a complete postmortem separation of the vertebral column between the 1st and 2nd lumbar vertebrae. The left femur was disarticulated from its acetabulum. A good portion of the soft tissue was absent. There was post-mortem absence over the right and left elbows. The distal epiphysis of the left ulna was not fused.

NECK: The hyoid bone was intact. There was hemorrhage into the tissue surrounding the hyoid bone. There was periesophageal hemorrhage. There was hemorrhagic discoloration of the larynx and first portion of the trachea on the inner surface. The thyroid cartilage was intact, but there was hemorrhage around the thyroid cartilage.

HEAD: The scalp was reflected in the usual coronal fashion. The calvarium was not remarkable. There were no skull fractures. The brain was mushy. The residual brain weighed 750 grams.

Following the autopsy, a second set of X-rays was made in order to attempt to determine the skeletal age of this individual.

The first film was an anteroposterior view of the chest and shoulders and included most of both humeri. The spine was intact. The ribs were intact. Both clavicles were visible. There was no evidence of a medial clavicular epiphysis. Most of both scapulae could be seen. The proximal humerus epiphyses were not fused. A distinct epiphyseal plate was visible in both. None of the anular epiphyses of the vertebral column appeared to be fused.

A film of the pelvis showed considerable rotation. Portions of both forearms and hands were visible. Technical detail of the latter was good, while the pelvis was underpenetrated. The distal epiphyses of the right radius was well defined. It was not fused, and there was a distinct epiphyseal plate.

The distal portion of the left radius was also well defined and also showed no fusion. In the pelvis, only the anterior portions of the iliac crest epiphyses were well visualized. These showed a distinct epiphyseal plate and appeared not to be fused. The proximal ends of the femurs were barely visible and could not be evaluated. Two of the left metacarpals were quite well demonstrated. Both appeared to have completely fused epiphyses.

Film of the knees showed a well defined epiphyseal plate in the distal femurs. Fusion, if any, was very early. The proximal tibial epiphyses were less well visualized, but there were cortical defects at the margins of the epiphyseal plates and these appeared not to be fused. The fibulae were not well visualized.

The fourth X-ray showed the feet and ankles in the dorsal plantar view. The distal ends of the long bones of the legs were not well visualized. The metatarsal epiphyses all appeared to be completely fused. The epiphyseal lines were present in several of the proximal phalanges. They were most clearly defined in the proximal phalanges of the great toes, particularly at the proximal ends. These appeared to be unfused or only partially fused, as there was some suggestion of cortical defect at the margins of the epiphyseal plates.

Based upon the X-ray criteria, the age was estimated to be approximately 15 to 18 years.

DENTAL EXAMINATION

Utilizing the Universal System, all of the third molars are partially erupted. The upper left central, number 9, and the upper left lateral, number 10, are avulsed. The upper right second bicuspid, number 4, has undergone a 180 degree rotation. The buccal and lingual cusps are reversed. Number 22 is in mesial labial rotation. Number 25 is in lingual version, blocked out by tooth 24 and 26. Number 26 is in mesial labial rotation and number 27 is in mesial labial rotation. Jaw relationships are normal. The peridental condition is average. Caries are noted as follows: the upper right second molar, number 2, has distal and occlusal pit caries. The upper right first molar, number 3, has distal and occlusal pit caries. There is occlusal caries on the upper left first bicuspid, number 12, on the upper left second bicuspid, number 13, on the occlusal and distal occlusal pits on the upper left first molar, which is tooth 14. Caries is present on the occlusal and distal pits on the upper left second molar, which is tooth 15, on the lower left second molar, occlusal caries, which is tooth 18. On the occlusal on the lower left second bicuspid, which is tooth 20, occlusal caries, on the lower right first bicuspid, which is tooth 28, and on the lower right second bicuspid, which is tooth 29, and an occlusal caries on the lower right second molar, which is tooth 31.



Paul G. Stimson, D.D.S., M.S.

~~View~~Case No. 74 - 3378

Decedent: _____ Race _____ Sex _____ Age _____

Address: _____

Death: FOUND August 10, 1973 Approx. Time 7:00 ~~A.M.~~ ~~P.M.~~
County, TexasPlace of Death: 2-1/2 miles south of Broaddus, Texas, off F.M. 3185, San Augustine,

Place of Inquest: _____

Date and Time of Inquest: _____ A.M.
P.M.

Location, Position, and Surroundings of Body:

The decedent was lying face upward in a grave.

Clothing: The decedent was nude.

Information: San Augustine County Sheriff's Department, San Augustine County, Texas, Deputy Sheriff Richard Davis furnished the following information on August 11, 1973, at the Harris County Morgue, Houston, Texas.

The decedent identified as "Unknown #22" was found about 7:00 a.m. on August 10, 1973, when Elmer Wayne Henley (suspect in this case) led San Augustine County Sheriff's Department, Sheriff John Hoyt to a gravesite located about 5-4 feet from the gravesite of William Ray Lawrence, near the above location. Henley identified the gravesite by several crossed sticks on top of the ground. He specifically remembered this gravesite inasmuch as he returned subsequent to the original burial of the decedent and found that something had dug into the ground about the gravesite. Henley then placed a masonite board over the hole and covered the board with a thin layer of earth under which there was a lime substance, under which there was a masonite board, under which was the hole in which the decedent was placed, rolled into a plastic covering and taped shut with silver colored air conditioning tape. Decomposition was advanced, according to the Deputy Sheriff. Scene photographs were taken by Department of Public Safety, Austin, Texas. The decedent was taken to Wyman Roberts Funeral Home in St. Augustine, Texas, on August 10, 1973, by Dr. Jack Pruitt of Lufkin, Texas. The diagnosis was strangulation. Deputy Davis said that Henley made the (over)

Property: There was no property involved.

Transferred to Morgue by:

Funeral Home Conducting Service:

statement that one of the Unknowns #20, #21, or #22 could be a boy named "Garcia".

H. C. Gregory

AUTOPSY REPORT

(Series No. 20) (NOT IN HO SERIES)

Name: Body No. 1, identified as William Ray Lawrence
 Date of Autopsy: August 10, 1973, 12:30 p.m.
 Place of Autopsy: Wyman Roberts Funeral Home, San Augustine, Texas
 Authority: San Augustine County, Texas Justice of the Peace C. A. Renfroe #1
 Autopsy Prosector: Jack Pruitt, M. D.

CIRCUMSTANCES: Body found buried near Broaddus, Texas, on the afternoon of Thursday August 9, 1973.

GROSS EXAMINATION: The unclothed body is fully wrapped in a thick transparent plastic sheet and tied with several lengths of thick cord resembling venetian blind cord about 1/8 inch in diameter. The body is that of a slender white adolescent male 68 inches in length, the weight not estimated. The scalp hair is light brown and straight, about shoulder length, 12 - 15 inches. The wrists are secured behind the body with fabric adhesive tape. The legs are similarly taped together just above the ankles. A noose of thick cord like that described around the original plastic wrapping is secured around the neck, typical of a "hangman's noose", with a loose end 12 inches long extending down the back. The tissues of the neck are compressed, and indicate that this was applied tightly before death.

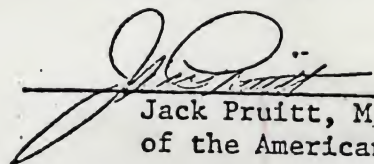
The skin is essentially intact over the entire body, although very slippery and having advanced postmortem decomposition, and there is no evidence of any penetrating wound. The outer skin surfaces over the fingers and toes have sloughed away, and make fingerprint identification impossible, according to two Texas Department of Public Safety Investigators present at the scene. The facial features can be recognized, although the nose has advanced decomposition, the bones intact, no recognizable evidence of trauma. Two teeth are out of their sockets, numbers 1 and 8 as indicated on the accompanying dental chart, postmortem in character, apparently all 32 teeth having erupted and having no evidence of decay or filling (see dental chart for description). The penis, scrotum and anus are intact, without evidence of mutilation, the pubic hair intact and recognizable.

The heart, lungs, and abdominal organs are shrunken and pasty, virtually unrecognizable, but without evidence of severe antemortem trauma.

According to information supplied by the father and the dentist, as well as a photograph published in the Houston Post, this body was identified as that of William Ray Lawrence, 15-year-old white boy. The condition of the body is consistent with a postmortem interval of approximately one month.

MICROSCOPIC EXAMINATION: Microscopic examination of the solid organs is of no value because of the severe postmortem decomposition of the tissues.

PATHOLOGIC DIAGNOSIS AND CAUSE OF DEATH: Death by strangulation, postmortem interval of about one month.


 Jack Pruitt, M. D., Diplomate
 of the American Board of Pathology

Original to Judge Renfroe
 Xerox copy to Sheriff Hoyt
 Xerox copy retained for files

Case #1 San Augustine 8-10-73

N-73-54

(Ident. as William Ray Lawrence)

NAME _____ DATE _____ AGE _____

FORM 1429 COLWELL CO., CHANPAIGN, ILL.

all teeth apparently in, but #1 out post-mortem, found in pharynx, no trauma; #8 out post-mortem, not found, no trauma - socket smooth, resembles #9. #9 (left upper medial incisor) larger & more prominent than others, small "chip" mesial tip, which if matched with absent #8 would form a notch. No recognized cavities, no fillings.

Other characteristics for identification:

1. Height 5'8", slender, weight not estimated.
2. Long straight brown hair, about shoulder length, est. 12-15 inches in longest portion.
3. Eyes apparently blue, but marked post-mortem decomposition.
4. Features resemble photo Houston Post Sun. 8-12-73

JOSEPH A. JACHIMCZYK, M.D., J.D.

FORENSIC PATHOLOGIST

ATTORNEY AT LAW

CHIEF MEDICAL EXAMINER



(713) 796-9292

(713) 796-6815



OFFICE OF THE MEDICAL EXAMINER OF HARRIS COUNTY
JOSEPH A. JACHIMCZYK FORENSIC CENTER

1885 OLD SPANISH TRAIL

HOUSTON, TEXAS 77054

January 17, 1995

Texas Department of Public Safety
Crime Laboratory
Danny Carter, Latent Prints
P. O. Box 4143
Austin, Texas 78765

Reference: 1973 Mass Murders; ML#73-3378
Unknown white male

Attached is the single print obtained from the unknown white male that I spoke with you about this date. This is the only print we were able to obtain so after your search could you please return it to us.

Thank you for your assistance in this matter.

Sincerely,

A handwritten signature in black ink, appearing to read "Pat Banks".

Pat Banks
Investigator

LAST NAME NAM

FIRST NAME

MIDDLE NAME

UNIDENTIFIED DECEDENT

STATE USAGE

ALIASES

CONTRIBUTOR

TX101023M
CO MED EXAM
HOUSTON, TX

SIGNATURE OF PERSON FINGERPRINTED

DATE OF BIRTH DOB
Month Day Year

THIS DATA MAY BE COMPUTERIZED IN LOCAL STATE AND NATIONAL FILES

DATE ARRESTED OR RECEIVED DOA

SEX

RACE

HGT

WGT

EYES

HAIR

PLACE OF BIRTH POB

DATE SIGNATURE OF OFFICIAL TAKING FINGERPRINTS

Found 8-9-73

M

W

5'7" -

11

bro

est. 18/22

CHARGE

Unidentified skeletal remains

FBI NO FBI

CLASS

SID NO SID


REF

FINAL DISPOSITION

SOCIAL SECURITY NO. SOC

NCIC CLASS - FPC

CAUTION

6. Left Thumb	7. Left Index	8. Left Middle	9. Left Ring	10. Left Little
				#10 

THE ABOVE INKED IMPRESSIONS OF FINGER # 10 WERE TAKEN FROM SKELETAL REMAINS RECOVERED FROM A MASS GRAVE IN 1973. THIS INDIVIDUAL HAD PROBABLY BEEN DEAD A YEAR OR SO WHEN THE BODY WAS RECOVERED ALONG WITH 23 OTHERS. THIS IS THE ONLY AND THE BEST FINGERPRINT AVAILABLE. IF ITS CONDITION IS SUCH AS NOT TO BE USABLE WE HAVE NO RECOURSE.

6 L THUMB

7 L INDEX

8 L MIDDLE

9 L RING

10 L LITTLE

Cecil Wingo
CECIL WINGO, CHIEF INVESTIGATOR
HARRIS COUNTY MEDICAL EXAMINER

FBI
Note ~~There is a~~
~~AFIS~~ AFIS DOES NOT INCLUDE
FINGER # 10

THIS IS OUR ONLY
FINGERPRINT.

LEFT FOUR FINGERS TAKEN SIMULTANEOUSLY

L THUMB

R THUMB

RIGHT FOUR FINGERS TAKEN SIMULTANEOUSLY

1.13.95
No fix - NCSO/AFIS

DPS would like to
run - they use a finger
data base -
DPS. Latents can
run -
TDPs - Danny Carter
Crime Lab -
PD Box 4143
Austin, TX
78763



U.S. Department of Justice

Federal Bureau of Investigation

Washington, D.C. 20537

Date: 6-9-93

Contributor:

The enclosed fingerprints and/or correspondence are being returned to you because of the reason(s) indicated below:

- (Contributor) (Registration) (Service) number omitted.
- Incomplete descriptive data.
- Indicate correct sex of subject.
- Name (not shown at top of card) (name and signature differ).
- Date of birth (not given) (not clear) (incomplete). If unknown, give approximate age.
- Charge and/or date of arrest not given.
- Inked finger impressions not on card.
- Advise reason for submission of fingerprints; if criminal, furnish charge; or, if applicant, furnish position for which applying.
- FBI number omitted. Rolled impressions of all ten fingers, plus plain impressions, must be submitted if FBI number not available.
- Advise if subject is deceased.
- Furnish final disposition.
- Impressions not black on standard white fingerprint card stock.
- Apparently mailed to us by mistake.
- Our records fail to reveal a statute from your state requiring fingerprinting for the position indicated on the enclosed card(s).
- There is no indication the enclosed cards and/or correspondence have been processed through your state identification bureau of central agency prior to submission to the FBI.
- Enclosed card may have been submitted by your office. Please list contributor, and return to FBI. If not submitted by your office, please advise.
- We do not include information unsupported by fingerprints in our files.
- Finger impressions on attached card are identical with those on file for subject of attached record; however, the description data on the card evidently pertains to another individual.
- Descriptive data on attached fingerprint card is similar to that on file for subject of attached record; however, finger impressions are for another individual.
- Finger impressions are identical with those on file for subject of FBI No _____; however, name and description are similar to information on file of subject of FBI No _____.
A copy of each record is attached.
- Search by name only has been conducted with negative results.
- Fingerprint search has been conducted with negative results.
- Essential information omitted; name, sex, descriptive data, DOB, fingerprints, person to be notified in case of emergency.
- Submit ten finger impression fingerprint card (refer to our letter to all fingerprint contributors dated 6/17/85, copy attached).
- Fingerprint card with nonserious offense/no arrest charges.
- Fingerprint card with missing/incorrect contributor's name and number.
- Fingerprint illegible - submit another fingerprint card.
- REJ/50 - Transaction received for processing matches NFF record from your state.
- REJ/51 - SID on file different than SID on print.
- REJ/52 - SID previously established for another FNU.
- REJ/53 - SID missing for NFF participant.
- Other **UNABLE TO PROCESS FINGERPRINT CARD WITH #10 FINGER ONLY.**

After making appropriate changes and/or additions, please resubmit. Your cooperation is appreciated.

Identification Division

Enclosure(s)

FBI/DOJ

1.13.95
No fix - NCSO/AFIS

~~DPS unable to
run - they use Springer
data base -~~

DPS Latents can
run -
TDPS - Parry Carter
Crime Lab Latents
PO Box 4143
Austerlitz
78763

LEAVE BLANK

TYPE OR PRINT ALL INFORMATION IN BLACK

LEAVE BLANK

LAST NAME NAM

FIRST NAME

MIDDLE NAME

UNIDENTIFIED DECEDENT

STATE USAGE

ALIASES

CONTRIBUTOR

 TX101023M
 CO MED EXAM
 HOUSTON, TX
DATE OF BIRTH DOB

Month Day Year

SIGNATURE OF PERSON FINGERPRINTED

THIS DATA MAY BE COMPUTERIZED IN LOCAL STATE AND NATIONAL FILES

DATE ARRESTED OR RECEIVED DOA

SEX

RACE

HGT.

WGT.

EYES

HAIR

PLACE OF BIRTH POB

DATE SIGNATURE OF OFFICIAL TAKING FINGERPRINTS

Found 8-9-73

M

W

5'5 1/2"
5'8"

bro

est. 18/22

CHARGE

Unidentified skeletal remains

FBI NO. FBISID NO. SIDSOCIAL SECURITY NO. SOC

LEAVE BLANK

CLASS

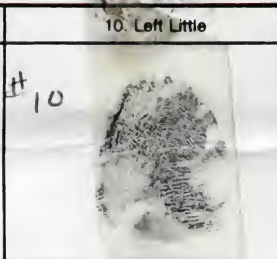
REF.

FINAL DISPOSITION

CAUTION



NCIC CLASS - FPC

6. Left Thumb	7. Left Index	8. Left Middle	9. Left Ring	10. Left Little
				#10 

5-45-93 THE ABOVE INKED IMPRESSIONS OF FINGER # 10 WERE TAKEN FROM SKELETAL REMAINS RECOVERED FROM A MASS GRAVE IN 1973. THIS INDIVIDUAL HAD PROBABLY BEEN DEAD A YEAR OR SO WHEN THE BODY WAS RECOVERED ALONG WITH 23 OTHERS. THIS IS THE ONLY AND THE BEST FINGERPRINT AVAILABLE. IF ITS CONDITION IS SUCH AS NOT TO BE USABLE WE HAVE NO RECOURSE.

6. L. THUMB

7. L. INDEX

8. L. MIDDLE

9. L. RING

10. L. LITTLE

Cecil Wingo
 CECIL WINGO, CHIEF INVESTIGATOR
 HARRIS COUNTY MEDICAL EXAMINER

FBI
 NOTE ~~THE FBI DOES NOT INCLUDE~~
~~THIS~~ AFIS DOES NOT INCLUDE
 FINGER # 10.

THIS IS OUR ONLY
 FINGERPRINTS.

LEFT FOUR FINGERS TAKEN SIMULTANEOUSLY

L. THUMB

R. THUMB

RIGHT FOUR FINGERS TAKEN SIMULTANEOUSLY

BURIAL-TRANSIT PERMIT

PERMIT
 NUMBER

LOCAL PERSON ON DECEASED	1. Full name of deceased <i>unknown</i>			2. Date of death (month, day, and year) <i>unknown</i>		3. Death due to communicable disease YES <input type="checkbox"/> NO <input checked="" type="checkbox"/>	
	4. Sex <i>male</i>	5. Color or race <i>white</i>	6. Age in years <i>unknown</i>	7. Place of death (city or precinct no.) <i>unknown</i>		(county)	(state)
MANNER AND PLACE OF DISPOSAL	Method of disposal Burial <input type="checkbox"/> Removal <input checked="" type="checkbox"/>		Cremation <input type="checkbox"/> Disinterment <input type="checkbox"/>		Place of burial (name of cemetery or crematorium) (city or town) (state) removal or disposal		
	Name of funeral director <i>Albert L. Godsey</i>			License number <i>6357</i>	Business address <i>801 304 618 San Augustine</i>		
Name of embalmer (if none, write none) <i>Albert L. Godsey</i>			License number <i>4823</i>	Business address <i>" " " " "</i>			
AUTHORIZATION TO DISPOSE OF BODY	A certificate of death having been filed as required by the laws of Texas and all laws and regulations governing the preparation and disposal of dead bodies having been complied with, permission is hereby given to dispose of the body as identified above.						
	Signature of local registrar <i>C. A. Renfro</i>			District (city or precinct no.) <i>Precinct #1 San Augustine</i>		(county)	Date <i>8-11-73</i>
DISPOSITION OF BODY	Body was Buried <input type="checkbox"/> Cremated <input type="checkbox"/>		Date		Name of cemetery or crematory		
			Location (city or town)		(county)	(state)	Name of sexton or person in charge

Cecil,

P.A. was not sure of what the FBI could or could not do. He suggested giving them a call to see.

Sorry we were unable to help.

Lisa
Wideman

no release
per first
file

2.6.95

Jerry
Wideman
SUPV.
FBI

JOSEPH A. JACHIMCZYK, M.D., J.D.

FORENSIC PATHOLOGIST

ATTORNEY AT LAW

CHIEF MEDICAL EXAMINER



(713) 796-9292

(713) 796-6815



OFFICE OF THE MEDICAL EXAMINER OF HARRIS COUNTY

JOSEPH A. JACHIMCZYK FORENSIC CENTER

1885 OLD SPANISH TRAIL

HOUSTON, TEXAS 77054

January 17, 1995

Texas Department of Public Safety
Crime Laboratory
Danny Carter, Latent Prints
P. O. Box 4143
Austin, Texas 78765

Reference: 1973 Mass Murders; ML#73-3378
Unknown white male

Attached is the single print obtained from the unknown white male that I spoke with you about this date. This is the only print we were able to obtain so after your search could you please return it to us.

Thank you for your assistance in this matter.

Sincerely,

A handwritten signature in cursive script, appearing to read "Pat Banks".

Pat Banks
Investigator

Luis A. Sanchez, M.D.
Chief Medical Examiner



(713) 796-9292
FAX : (713) 796-6844

JOSEPH A. JACHIMCZYK FORENSIC CENTER

August 26, 2008

Kathy Parks
Shift Supervisor
Fingerprint Section
Crime Records Service
5805 N. Lamar Blvd.
Box 4143
Austin, Texas 78765-4143

Dear Ms. Parks:

Attached is the original ink #10 fingerprint from our case ML73-3378. This is an unknown white male, 15-17 years old, 5'8" – 5'10" tall, with an approximate DOD of May-July 1973. This is the only print that the HCME was able to obtain from the decedent. We are in the process of comparing this decedent with a missing person, Rodney Lee Harris, DOB 12/14/1956. Thank you in advance for working on this.

As this is the only original copy we have, please return it by secure mail as soon as possible.

Sincerely,

Sharon M. Derrick

Sharon M. Derrick, PhD
Agency Coordinator/Anthropologist
713-796-6858
sharon.derrick@meo.hctx.net

Cc: Ms. Blanca Garcia
Ms. Barbara Callistien
Original Case File ML73-3378